


Regenerative Medicine: Urinary Bladder Matrix* assistance with High Risk Diabetic Limb Salvage

Joseph Gonzalez, DPM
The Foot Wound Institute
Capital Foot & Ankle Centers, Okemos, Michigan

Study # LIT000

This study was sponsored by:

Educare[™]
wound & skin care education

The clinical education division of 

©2007 Medline Industries, Inc. One Medline Place, Mundelein, IL 60060
Medline and Educare are registered trademarks of Medline Industries, Inc.
1-800-MEDLINE (1-800-633-5463) www.medline.com

MKT000000/LIT000/2.5M/K&M7

Regenerative Medicine: Urinary Bladder Matrix* assistance with High Risk Diabetic Limb Salvage

The infected foot ulcer is the most common reason for hospitalization among patients with diabetes. Severe limb threatening wounds continue to pose a serious challenge for the wound care experts. The case series presented here discusses the wound healing potential of a “next-generation” form of Bioengineered Tissue derived from the porcine Urinary Bladder Material (UBM) that contains a relatively intact Basement Membrane along with other components associated with Extracellular Matrix (ECM). This Basement Membrane/ECM Wound Matrix* is a naturally occurring, non-crosslinked, completely resorbable acellular biomaterial. The unique characteristic of the basement membrane is ideal for epithelial cell growth in many applications.¹ The Basement Membrane/Wound Matrix contains multiple collagen types, proteoglycans, multiple growth factors, glycoproteins and anti-infective peptides.²

Four Case Studies are presented here, each involving the healing of a severe, high risk diabetic foot wound. Basement Membrane/ECM Wound Matrix was utilized to heal the wound and prevent amputation in all four cases. These cases include diabetic patients with: 1) an abscess on the lateral foot, 2) a partially exposed plate following a calcaneal ORIF, in which the patient was able to retain the hardware, 3) a deep, tunneling abscess in the first innerspace, and 4) A septic ankle joint with “blow-out” wounds at the medial and lateral foot/ankle in a patient with a contralateral BKA, as well as Rheumatoid Arthritis.

In each case, treatment led to sequential visual evidence of complete healing with the use of Urinary Bladder Membrane technology. The clinic used culture driven IV antibiotics concurrently with the UBM extracellular matrix to achieve healing.

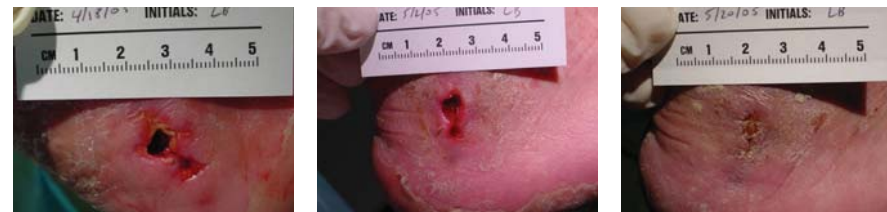INTRODUCTION AND BACKGROUND

Relatively recently, and in parallel with the understanding of the key role of ECM (Extracellular Matrix) in wound healing, biomaterial science has evolved allowing the harvesting and processing of biological tissue into high quality biomaterials suitable for regular clinical use. For example, the acellular ECM that is the subject of this study, isolated from the porcine bladder, or other similar materials isolated from the intestinal submucosa, are complex multicomponent biomaterials that have potential for making transformational changes in the practice of wound healing.

In the context of wound healing, of particular significance is the use of the Basement Membrane layer in the ECM material* studied in this case series. One of the best sources of an easily harvestable and reliable source of the acellular basement membrane ECM is the porcine urinary bladder material or UBM.

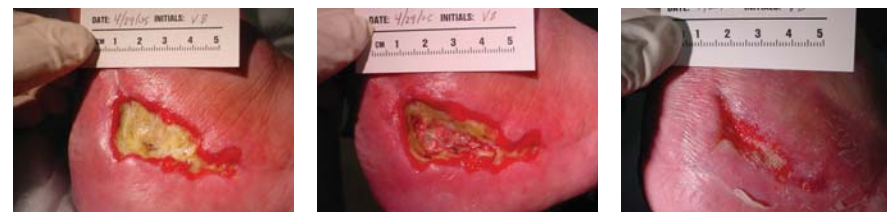CASE 1

A 32 year-old male with a past medical history for poorly controlled type II diabetes with peripheral neuropathy presented with a 1 week history of an abscess at the lateral aspect of his right heel. He could not recall any trauma to the area or any other inciting events. He stated that he recently noticed a red, swollen blister with pus draining. Upon presentation, his vascular status was intact and he had a deep, tunneling abscess, just anterior to the Achilles tendon on the lateral aspect of his heel. The wound measured 0.5cm x0.7 cm with 1.5 cm of depth. The abscess was initially drained and debrided. ECM/Basement Membrane material was packed into the deep tunnel and covered with Adaptic® and a mildly compressive dressing. The patient was given a post-op shoe to wear. He returned weekly for serial debridements, at each visit the ECM/Basement Membrane was packed into the wound at each visit. At 4.5 weeks, the wound had epithelialized completely.



CASE 2

A 43 year-old female with a past medical history of type II diabetes with neuropathy was involved in a motor vehicle accident, causing displaced fracture of her right calcaneus. She underwent open reduction with internal fixation with plate and screws two days later. At her two-month follow-up appointment, it was noted that the incision had not healed, and she visited the wound center for treatment. Upon initial presentation, her vascular status was intact and the corner of the wound had dehisced and was completely fibrotic at the plantar lateral heel with a small corner of the plate exposed. Sharp debridement was performed to remove the fibrotic tissue. The wound was covered with Basement Membrane/ECM Wound Matrix, covered with Adaptic® and negative pressure wound therapy was implemented. The patient was already prescribed a six-week course of IV antibiotics and was seen weekly for serial debridements and local wound care with the Basement Membrane/ECM Wound Matrix was applied every 7 days. Within three weeks, the wound had granulated completely over the exposed plate. Weekly debridements and Basement Membrane/ECM Wound Matrix application was continued, however edema control was difficult to achieve due to poor patient compliance. Appropriate compression therapy was utilized with the Basement Membrane/ECM Wound Matrix and the wound healed after 20 weeks without the need for hardware removal or aggressive surgical intervention.

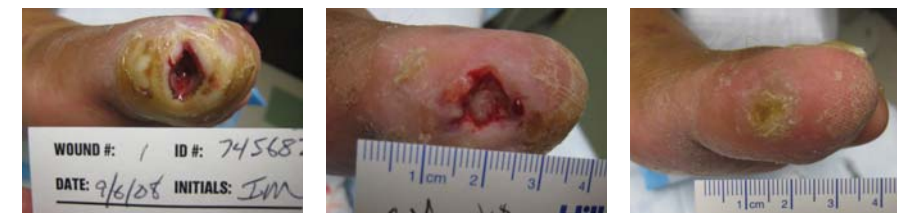

The Wound Center where this study was done, is developing a protocol of using this UBM derived Basement Membrane containing various ECM associated biomolecules to “fill” a tissue defect, hypothesizing that the complex interplay of the Basement Membrane components will provide the ability to recruit progenitor cells that may progress on to differentiate into a number of tissue types that fill the wound as nature intended.

In this study we used the ECM/Basement Membrane material on a series of diabetic wounds that had resisted all efforts in healing. Each patient had significant co-morbidities and associated problems, the objective of the study was to note if the ECM/Basement Membrane material would change the dynamics of a wound that is stalled in a pernicious state of equilibrium with no healing observed over weeks and months using other advanced treatment methods.

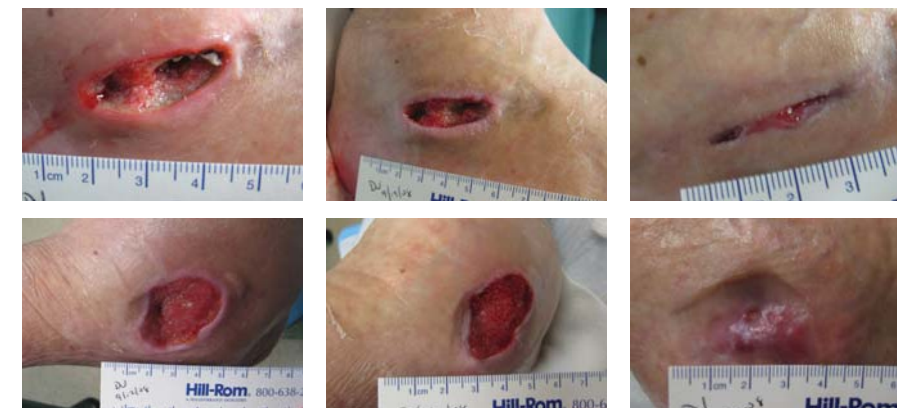CASE 3

A poorly controlled, type II diabetic female presented with an abscess in her left hallux which had been present for at least one week. She had peripheral neuropathy and her vascular status was noted to be intact. She had a red, hot, swollen, deep, tunneling ulceration at the left hallux distal phalanx which measured 0.6cm x 1.0cm x 1.0cm deep. It did probe to bone and she was placed on antibiotic driven IV antibiotics for six-weeks. The wound was debrided down to healthy bleeding tissue and then packed with Basement Membrane/ECM Wound Matrix and covered with an Adaptic® and mildly compressive dressing. She was placed in an accommodated surgical shoe. She returned weekly for serial debridements and Basement Membrane/ECM Wound Matrix was packed into the wound at each visit. Within four weeks, the wound had granulated to the surface. Basement Membrane/ECM was continued until wound closure at twelve weeks.



CASE 4

A 63 year-old female with a past medical history significant for type II diabetes with neuropathy, rheumatoid arthritis, Charcot neuroarthropathy right ankle and left below-knee-amputations was seen in the hospital for a septic right ankle joint, present for one week. The infection source was noted to be from a staple in the talonavicular joint and was surgically removed. The patient was offered a right below-knee-amputation and subsequently refused, as she still was not ambulating from the previous left below-knee-amputation three months earlier. Wound Center consultations were sought for limb salvage options. The initial medial wound over the talonavicular joint measured approximately 5.0cm x 5.0cm and tunneled to the ankle joint, causing a lateral blow out of the ankle and a second wound measuring 3.0cm x 1.5cm. There was a significant amount of purulent drainage, as well as erythema and edema. A thorough bedside debridement was performed and dilute betadine irrigation was utilized for three days. Once the purulent drainage was reduced to a minimum, Basement Membrane/ECM Wound Matrix was packed into the tunneling wounds and negative pressure wound therapy was utilized. The patient was discharged on an 8-week course of culture specific antibiotics and followed up weekly at the Wound Center. Serial debridements were utilized with continued use of Basement Membrane/ECM Wound Matrix and negative pressure wound therapy. Compression therapy was utilized following negative pressure wound therapy, and the wounds subsequently healed after three months of treatment. The patient was able to utilize her prosthetic on the left below-knee amputation and is currently increasing her ambulation in physical therapy. We continue to use compression therapy to control the edema, but the medial wound continues to open and close periodically due the excessive shoe pressure on this prominent area of her Charcot foot.



DISCUSSION OF RESULTS

A newly available Basement Membrane containing Extracellular Matrix (ECM) Wound Sheet* has properties that may augment the natural wound healing process which is severely compromised in patients with complex co-morbidities. In addition to moist wound healing practices, it is possible that such complex biomaterials, which have the ingredients that have proven ability to recruit wound healing cells, can make a real difference in disturbing the non healing equilibrium associated with the chronic wound. It is also possible that these technologies will be the used in the healing of chronic wounds of the future, now that the concept of “active” wound healing is now possible in a large measure. We believe that the remarkable healing that was demonstrated on four patients with non healing diabetes associated wounds through the use of the Urinary Bladder Material with Basement Membrane and other Extracellular Matrix (ECM) components saved significant resources, pain and time. More research in this area is intended in future.

CONCLUSION

Urinary Bladder Membrane containing the Basement Membrane and other Extracellular Matrix (ECM) components is an effective product to assist in healing of all diabetic ulcers, including severe, limb threatening wounds.

REFERNECES

1. Brown B, Lindberg K, Reing J, Stolz DB, Badylak SF. The basement membrane component of biologic scaffolds derived from extracellular matrix. *Tissue Eng.* 2006 Mar;12(3):519-26.
2. Brennan EP, Reing J, Chew D, Myers-Irvin JM, Young EJ, Badylak SF. Antibacterial activity within degradation products of biological scaffolds composed of extracellular matrix. *Tissue Eng.* 2006 Oct;12(10):2949-55.

* MatriStem®, distributed by Medline Industries, Mundelein, IL.