

# The Next Generation: The Use of Basement Membrane and Extracellular Matrix containing Urinary Bladder Matrix\* in the treatment of Chronic Venous Ulcerations


Joseph Gonzalez, DPM  
The Foot Wound Institute  
Capital Foot & Ankle Centers, Okemos, Michigan

---

Study # LIT000

*This study was sponsored by:*

*Educare*<sup>™</sup>  
wound & skin care education

The clinical education division of  **MEDLINE**

©2007 Medline Industries, Inc. One Medline Place, Mundelein, IL 60060  
Medline and Educare are registered trademarks of Medline Industries, Inc.  
1-800-MEDLINE (1-800-633-5463) [www.medline.com](http://www.medline.com)

MKT000000/LIT000/2.5M/K&M7

# The Next Generation: The Use of Basement Membrane and Extracellular Matrix containing Urinary Bladder Matrix\* in the treatment of Chronic Venous Ulcerations

Up to 80% of leg ulcers are the result of chronic venous hypertension, most commonly caused by valvular incompetence. Various products have been proven to be effective for treatment under compression therapy, including extracellular matrix technology.

Naturally derived, non-crosslinked extracellular matrix, such as those derived from Urinary Bladder Materials (UBM), are unique among scaffold technologies which fundamentally change healing through the deployment of significant biomolecules that have the capacity to engage cells involved in natural wound healing, including progenitor cells that differentiate to fully functional adult cells in site specific tissues. Specifically, preclinical research shows that the basement membrane component of the product described here, allows increased activity from a wound healing perspective, as it contains multiple collagen types, proteoglycans, multiple growth factors, glycoproteins and anti-infective peptides<sup>1,2</sup>. During the healing process, the Basement Membrane containing Wound Matrix\*, which is the product studied in this case series is known to be resorbed and replaced with new tissue where scar tissue would normally be expected.

The experience at a busy wound center using this novel biomaterial, the Basement Membrane/ECM Wound Matrix, are presented in a case study series on four patients with chronic venous ulcers with varying degrees of complexity. Included are photographs revealing the product, the recommended application of the product, and sequential images showing the wound healing over time.

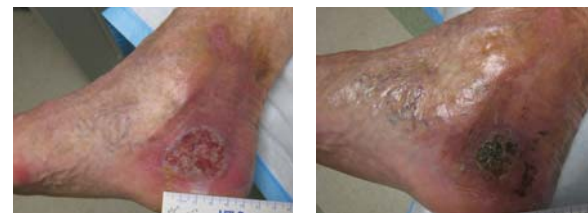## INTRODUCTION AND BACKGROUND

Relatively recently, and in parallel with the understanding of the key role of ECM (Extracellular Matrix) in wound healing, biomaterial science has evolved allowing the harvesting and processing of biological tissue into high quality biomaterials suitable for regular clinical use. For example, the acellular ECM that is the subject of this study, isolated from the porcine bladder, or other similar materials isolated from the intestinal submucosa, are complex multicomponent biomaterials that have potential for making transformational changes in the practice of wound healing.

In the context of wound healing, of particular significance is the use of the Basement Membrane layer in the ECM material\* studied in this case series. One of the best sources of an easily harvestable and reliable source of the acellular basement membrane ECM is the porcine urinary bladder material or UBM.

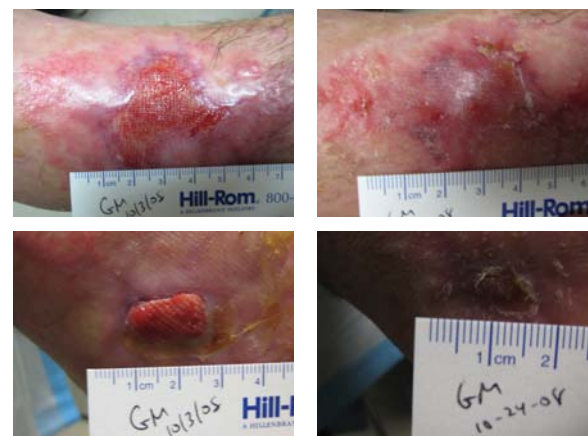## CASE 1

A 58 year-old male with a past medical history significant for chronic venous insufficiency presented to the Wound Center with a large venous wound on the medial aspect of his right heel. Initially, he was treated with silver or collagen products and covered with weekly four-layer compression dressings. After two months with minimal healing, he was treated with the Basement Membrane/ECM Wound Matrix fixated in place with Steri-strips™ and covered with foam and a four-layer compression dressing. The wound was debrided weekly and the compression was continued on a weekly basis. In the last two weeks of healing, the patient was treated with the Basement Membrane/ECM Wound Matrix and covered with a silver impregnated foam dressing under the compression wrap for healing. The wound healed in seven weeks following the initiation of the Basement Membrane/ECM Wound Matrix.



## CASE 2

A 41 year-old male presented to the Wound Center 3 months status post ORIF right tibial plateau fracture, ORIF right ankle fracture, and decompression of compartment syndrome right leg with skin grafting following a traumatic snowmobile accident. The patient's past medical history is significant for chronic venous insufficiency as well as hypertension. The surgeons had attempted skin grafting on the wounds at the same time as the leg skin grafting with continued areas of non-healing. Upon initial evaluation, the patient had significant venous edema in the right lower extremity with a large anterior ankle wound and a small venous wound laterally. Both were healthy and granular, with no signs of infection, yet remained open for three months. Therefore, Basement Membrane/ECM Wound Matrix was applied, fixated with Steri-strips™, and covered with Adaptic® and a four-layer compression wrap. The patient returned weekly for dressing changes and serial debridements, including a debulking of the hypergranular tissue laterally. Each week, a new piece of Basement Membrane/ECM was applied and four-layer compression was continued. The wounds were completely healed after seven weeks; the patient was placed in a custom-made knee-high compression stocking and discharged with a healed outcome.

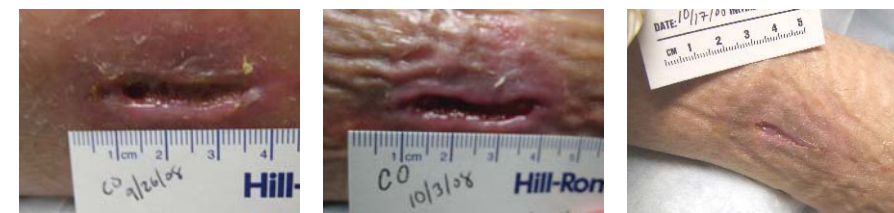

The Wound Center where this study was done is developing a protocol of using this UBM derived Basement Membrane containing various ECM associated biomolecules to "fill" a tissue defect, hypothesizing that the complex interplay of the Basement Membrane components will provide the ability to recruit progenitor cells that may progress on to differentiate into a number of tissue types that fill the wound as nature intended.

In this study we used the ECM/Basement Membrane material on a series of venous insufficiency associated wounds that had resisted all efforts in healing. Each patient had significant co-morbidities and associated problems, the objective of the study was to note if the ECM/Basement Membrane material would change the dynamics of a wound that is stalled in a pernicious state of equilibrium with no healing observed over weeks and months using other advanced treatment methods.

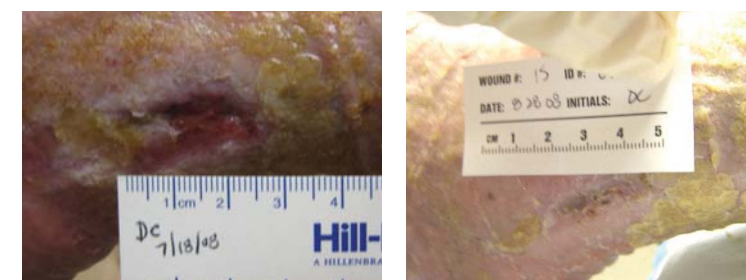## CASE 3

A 66 year-old female presents to the Wound Center 16-weeks status post ORIF of a right fibula fracture. The initial incision had yet to heal due to the patient's chronic venous insufficiency. The subject's other significant past medical history includes COPD and hypertension. Upon initial presentation the proximal one-third of her incision remained open with no exposed hardware. Xrays revealed adequate fixation across the fracture with a semi-tubular plate and screws. The fracture was well-healed and the screws appeared to be intact with no sign of infection or loosening. Therefore, Basement Membrane/ECM Wound Matrix was applied, fixated with Steri-strips™, and covered with adaptic and a four-layer compression wrap. The patient returned weekly for serial debridements and continued application of the Basement Membrane/ECM Wound Matrix and compression wrap. The wound healed in three weeks. She was placed in custom-made knee-high compression stockings and discharged with a healed outcome.



## CASE 4

An 87 year-old male presented to the Wound Center with a new venous ulceration at the lateral aspect of his left ankle. His past medical history included recurrent slow-healing, venous wounds as well hypertension. For the initial two months, he was treated for the ulceration with silver dressings, collagen, and Apligraf® with minimal improvement. Two months following the application of Apligraf, he was treated with the Basement Membrane/ECM Wound Matrix and covered with Adaptic® and a two-layer compression dressing. The patient continued to return weekly for serial debridements and treatment with Basement Membrane/ECM Wound Matrix covered with compression wraps. Six weeks after the initial application of Basement Membrane/ECM Wound Matrix, the wound was completely healed.



## DISCUSSION OF RESULTS

A newly available Basement Membrane containing Extracellular Matrix (ECM) Wound Sheet\* has properties that may augment the natural wound healing process which is severely compromised in patients with complex co-morbidities. In addition to moist wound healing practices, it is possible that such complex biomaterials, which have the ingredients that have proven ability to recruit wound healing cells, can make a real difference in disturbing the non healing equilibrium associated with the chronic wound. It is also possible that these technologies will be the used in the healing of chronic wounds of the future, now that the concept of "active" wound healing is now possible in a large measure. We believe that the remarkable healing that was demonstrated on four patients with non healing venous insufficiency associated wounds through the use of the Urinary Bladder Material with Basement Membrane and other Extracellular Matrix (ECM) components saved significant resources, pain, and time. More research in this area is intended in future.

## CONCLUSION

The use of Urinary Bladder Material derived Basement Membrane/ECM Wound Matrix\* is shown to be effective in the treatment of chronic venous ulcerations.

\*MatriStem®, distributed by Medline Industries, Mundelein, IL.